



PATIENT

BJ Sullivan

SPECIES

Canine

BREED

Terrier Mix

SEX

Male Neutered

AGE

10 years

WEIGHT

8lbs

INTERPRETED BY

Maggie Machen
Lamy, DVM
DACVIM (Cardiology)

IMAGING PERFORMED BY

Pamela Harrigan,
RDCS

HOSPITAL NAME

Barnstable Animal
Hospital

REFERRING VET

Dr. Ware

INVOICE

24752

DATE

6/13/22

PRESENTING CLINICAL SIGNS

History: Presented to ER for coughing - radiographs showed no signs of CHF - diffuse bronchointerstitial pulmonary pattern noted. Given history of coughing, chronic lower airway disease should be considered; left-sided cardiac enlargement c/w mitral valve disease. Was started on furosemide 6.25mg BID and Pimobendan 1mg BID. BJ is doing well at home. BP: 130mmHg

ECHOCARDIOGRAM FINDINGS

2D, m-mode, color flow and Doppler imaging is available.

Left ventricle: Mild LV dilation with hyperdynamic function. LV wall thicknesses are normal.

Left atrium: The left atrium is severely enlarged and bulbous in appearance.

Mitral valve: Diffuse thickening of mitral valve leaflets (anterior > posterior) with marked prolapse into the left atrial lumen. Severe mitral regurgitation. Normal velocity.

Aortic valve/Aorta: The aortic valve is normal in morphology and mobility. No AI. Normal LVOT velocity.

Right ventricle: Normal RV dimension. No obvious RVH.

Right atrium: Mild atrial dilation.

Tricuspid valve: The tricuspid valve appears thickened with minimal septal prolapse. Moderate tricuspid regurgitation visualized. Velocity consistent with mild pulmonary hypertension.

Pulmonic valve/Pulmonary artery: The pulmonic valve is normal with normal pulmonic outflow velocity. No pulmonic insufficiency.

Pericardium/other: No pericardial or pleural effusion noted. No obvious cardiac masses.

Heart rhythm: ECG reveals a sinus rhythm with an average HR of 120bpm.

2-Dimensional Measurements

Ao diam (cm)	1.3
LA diam (cm)	2.5
LA:Ao (Swe)	1.95
IVS thickness (cm)	0.55
LVID diastole (cm)	2.66
PW thickness (cm)	0.56
LVID systole (cm)	0.9
FS (%)	67

Doppler Measurements

PV Vmax (m/s)	0.8
AoV Vmax (m/s)	1.6
MR Vmax (m/s)	5.4
TR Vmax (m/s)	2.8
TR PG (mmHg)	32

INTERPRETATION OF THE FINDINGS

Chronic degenerative valve disease causing severe mitral and moderate tricuspid regurgitation. Severe LA dilation indicates the risk for spontaneous congestive heart failure is high going forward. Early pulmonary hypertension is noted which should be monitored going forward. No additional issues such as systolic dysfunction is identified.

In light of a reported cough and severity of disease on echocardiogram, there is concern for early congestive heart failure even without reported congestion on films. Continued full cardiac supportive medications is recommended as below, including low-dose Lasix therapy. Hydrocodone should also be considered for quality of life for any mechanical component.

The average survival time of canine patients with active pulmonary edema is 8-9 months on medications, however they generally are able to maintain a good quality of life for that



PATIENT

BJ Sullivan

period. Patient will always be at risk for recurrent CHF, development of arrhythmias/LA tear, syncope and/or sudden death in the future.

SPECIES

Canine

BREED

Terrier Mix

SEX

Male Neutered

AGE

10 years

WEIGHT

8lbs

RECOMMENDATIONS

- Administer Furosemide 1mg/kg PO q12h.
- Administer Pimobendan 0.3mg/kg PO q12h.
- Institute Spironolactone 1-2mg/kg PO q12h.
- Pending response, consider hydrocodone with homatropine 0.2-0.4mg/kg up to q4-6 hours PRN for any residual mechanical cough in the face of normal sleeping respiratory rates.
- Monitor for development of a cough, labored breathing, exercise intolerance or collapse episodes.
- Monitoring of sleeping respiratory rates will be paramount to screen for congestive heart failure at home.
- Elective anesthesia is not advised.
- Omega fatty acid supplementation and mild salt restriction may be of some long-term benefit.

PLAN

- Monitor renal values and BP in 1-2 weeks. If BP >130mmHg, institute ACEI 0.5mg/kg PO q12h. Monitor renal panel/BP every 3-4 months lifelong.
- Recommend conservative monitoring with a recheck echocardiogram in 4-6 months, sooner if any development of clinical signs.

INTERPRETED BY

Maggie Machen Lamy, DVM
 DACVIM (Cardiology)

IMAGING PERFORMED BY

Pamela Harrigan, RDCS

HOSPITAL NAME

Barnstable Animal Hospital

REFERRING VET

Dr. Ware

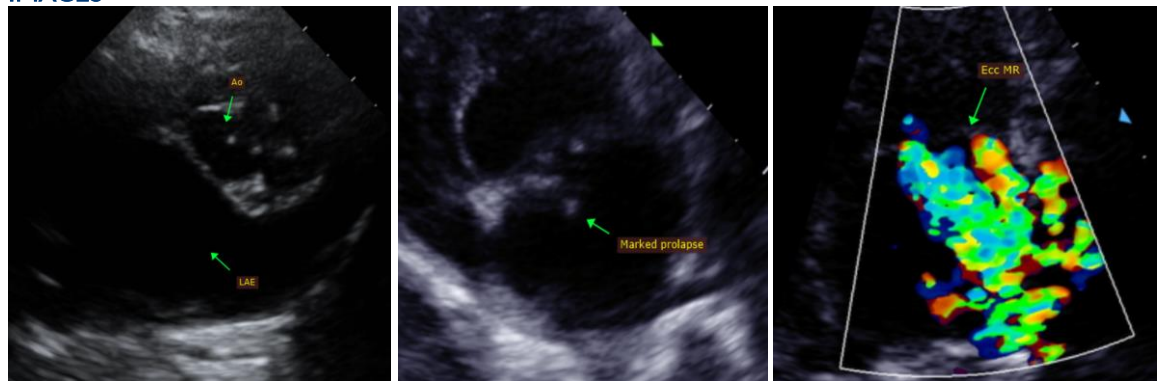
INVOICE

24752

DATE

6/13/22

IMAGES



The information and recommendations provided are based on the images presented by the referring veterinarian. No evaluation can be communicated regarding pathology that was not visible in the image/video clips provided.

Thank you for this referral. This report was generated using transcription software, and minor dictation errors may be present. If the clinical or image interpretation does not parallel your findings or if I can be of any further assistance, please contact me.

Maggie Machen Lamy, DVM
 Diplomat of the American College of Veterinary Internal Medicine (Cardiology)
 info@sonopath.com